

# Brain White Matter Impairment in Congenital Adrenal Hyperplasia

Roberto Bergamaschi, MD; Chiara Livieri, MD; Carla Uggetti, MD; Elisa Candeloro, PhD; Maria Grazia Egitto, MD; Anna Pichiecchio, MD; Vittorio Cosi, MD; Stefano Bastianello, MD

**Background:** Congenital adrenal hyperplasia (CAH) is an inherited recessive disorder of adrenal steroidogenesis. Past reports suggested that brain white matter could be involved in CAH.

**Objective:** To detect the presence, and possible changes over time, of brain white matter abnormalities in patients with CAH.

**Design:** Neurological examination and brain magnetic resonance imaging (MRI) that were repeated in 12 patients after a mean interval of 11 years.

**Setting:** Pavia, northern Italy.

**Patients:** Twenty-two patients with CAH.

**Main Outcome Measures:** Evaluation of clinical neurological findings and brain MRI T2-weighted images.

**Results:** Ten (45%) of 22 patients with CAH had white matter abnormalities (diffuse in 4 cases, focal in 3 cases, and both diffuse and focal in 3 cases) on MRI. The MRI findings never changed over repeated assessments.

**Conclusions:** Subclinical brain white matter involvement is frequent in CAH. This might be due to hormonal imbalance during brain development or corticosteroid treatments. Our study findings indicate that a relationship with demyelinating diseases can also be suggested. Diagnosis of CAH should be suspected in young subjects with brain MRI white matter abnormalities that are not otherwise explicable.

*Arch Neurol.* 2006;63:413-416

**C**ONGENITAL ADRENAL hyperplasia (CAH) is an autosomal recessive disease, characterized by 21 $\beta$ -hydroxylase deficiency.

The considerable cascade of hormonal modifications produced by 21 $\beta$ -hydroxylase deficiency, such as underproduction of cortisol and aldosterone, as well as overproduction of corticotropin, 17-hydroxyprogesterone, and androgens, could represent a noxious environment for the brain.

In the past, only a few studies described brain magnetic resonance imaging (MRI) abnormalities in CAH.<sup>1-3</sup> In a previous Italian study,<sup>1</sup> white matter abnormalities were found in 4 (27%) of 15 cases of CAH. In addition, Bergamaschi et al<sup>4</sup> described a patient who had CAH and multiple sclerosis.<sup>4</sup> To verify these observations and to evaluate possible changes over time, neurological and brain MRIs were repeated in some of the patients with CAH included in the previous cohort,<sup>1</sup> and performed for the first time in other patients with CAH.

**Author Affiliations:** From the Multiple Sclerosis Center (Drs Bergamaschi and Candeloro), Service of Neuroradiology (Drs Uggetti, Egitto, Pichiecchio, and Bastianello), and Department of Neurology (Dr Cosi) of the Neurological Institute "C. Mondino," and from the Department of Applied Health Sciences (Dr Livieri), University of Pavia, Pavia, Italy.

## METHODS

We studied 22 patients with CAH (13 females, 9 males; mean age at first examination, 19.9 years; age range, 16-25 years). Congenital adrenal hyperplasia was related to 21 $\beta$ -hydroxylase deficiency in all patients. The diagnosis was also confirmed in 14 patients by the detection of a *CYP21* gene mutation on chromosome 6.

Nineteen patients were classified as having the classic clinical form of CAH—7 had a simple virilizing subtype and 12 had the more severe salt-wasting subtype. Three patients had a non-classic late-onset form. None of the patients was treated in utero with corticosteroids.

All patients received a combination treatment of hydrocortisone and fludrocortisone. The average age at onset of glucocorticoid therapy was 10.9 days (range, birth to 6 weeks) for the 12 patients with the salt-wasting subtype, and 2.5 years (range, 6 months to 4 years) for the 10 non-salt losers (ie, 7 patients with the simple virilizing subtype and 3 patients with the late-onset form). All patients with CAH gave their informed consent to participate in the study and underwent neurological examination and brain MRI.

**Table. Clinical and Brain Magnetic Resonance Imaging Findings of 22 Patients With Congenital Adrenal Hyperplasia**

Patient No./ Sex/Age, y*	Phenotype	DWMA	FWMA
1/M/24	SV	-	-
2/F/25	SV	-	-
3/F/19	SW	-	-
4/F/23	SW	-	+
5/M/22	SV	+	+
6/F/24	SW	-	-
7/F/21	SW	+	-
8/F/21	SV	+	-
9/F/18	LO	-	-
10/M/19	SV	-	+
11/M/17	SW	+	-
12/F/17	SW	-	-
13/F/18	SW	+	-
14/F/16	LO	-	-
15/F/22	SW	-	-
16/M/16	SV	+	+
17/M/18	SW	-	+
18/M/22	SV	-	-
19/F/23	LO	-	-
20/M/18	SW	+	+
21/F/17	SW	-	-
22/M/18	SW	-	-

Abbreviations: DWMA, diffuse white matter abnormalities; FWMA, focal white matter abnormalities; LO, late onset; SV, simple virilizing; SW, salt wasting; -, absent; +, present.

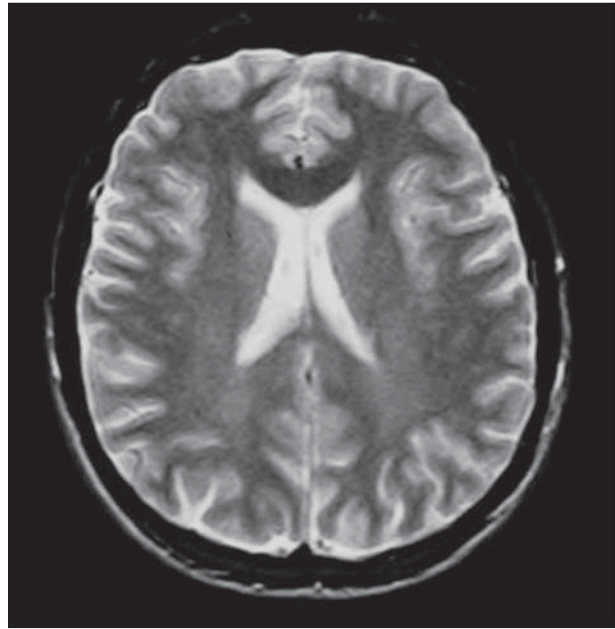
\*Age refers to the patient's age when the first magnetic resonance image was performed. Boldfaced patient numbers indicate those patients who had repeated clinical examinations and magnetic resonance imaging.

Ten patients were studied for the first time. Twelve patients were already included in a previous study<sup>1</sup> and repeated MRI assessment after a mean interval of 11 years (range, 10.6-11.4 years); we just included those patients reachable again, without specific selection criteria. Brain MRI was performed using a 0.5-T scanner (Philips Gyroscan NT; Philips Medical System, Best, the Netherlands). In the case of repeated examinations, we used the same scanner. Sagittal T1-weighted sections, axial proton density T2-weighted sections, and coronal turbo spin-echo T2-weighted and fluid-attenuated inversion recovery (FLAIR) sections were used.

White matter abnormalities, defined as areas of increased signal intensity on intermediate and T2-weighted sequences, were evaluated by 2 expert neuroradiologists (M.G.E. and C.U.). White matter changes on MRI were defined with a visual rating scale using a simplified scale.<sup>5</sup> White matter changes were defined as diffuse if visible as ill-defined bilateral hyperintensities on both T2-weighted, proton density and FLAIR images. Focal lesions were defined as well-defined areas of hyperintensities on T2-weighted, proton density and FLAIR images and spatially distributed considering the deep white matter, the subcortical areas, the corpus callosum, the basal ganglia, and the infratentorial location.

## RESULTS

Patients with CAH had no history of neurological symptoms. Neurological examinations revealed tendon reflexes asymmetry in 3 patients and mild vibration impairment in 1 patient. Clinical and MRI findings are summarized in the **Table**.



**Figure 1.** Diffuse white matter abnormalities in a 22-year-old man affected by simple virilizing congenital adrenal hyperplasia.

Ten patients (45%) had white matter abnormalities: only diffuse in 4 cases (**Figure 1**), only focal in 3 cases, and both diffuse and focal in 3 cases. Focal abnormalities were periventricular and paraventricular; an exception was made for an abnormality located in corpus callosum (**Figure 2**).

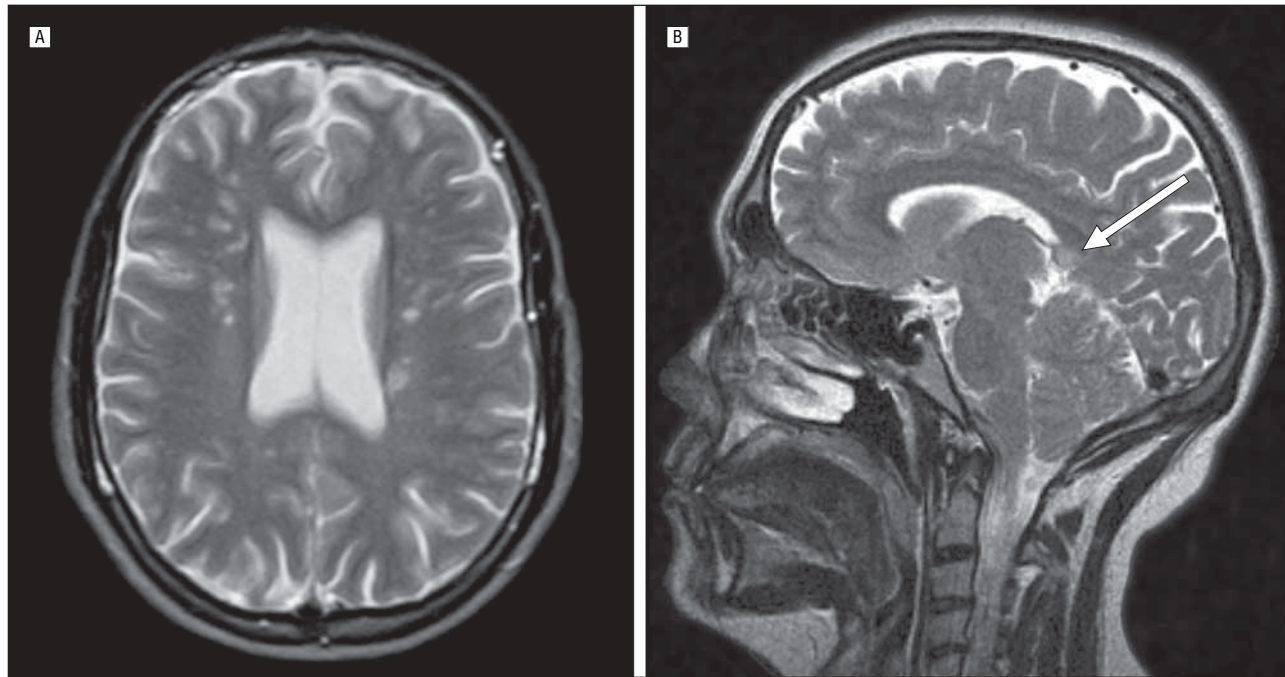
Among the 12 patients who had 2 MRIs, 7 (58%) showed abnormalities on the first MRI (2 diffuse, 3 focal, and 2 both focal and diffuse), which were unchanged on the second MRI. The 5 patients with a normal MRI on the first assessment had no abnormality on the second assessment.

We looked for possible correlations between MRI findings (normality, diffuse abnormalities, focal abnormalities) and clinical features (sex; phenotype: simple virilizing subtype, salt-wasting subtype, or late-onset form; duration of the disease; and time of treatment), performing univariate (Fisher exact test) and multivariate analyses (logistic multiple regression). No significant relationship was detected.

## COMMENT

Congenital adrenal hyperplasia is an interesting natural model for studying interactions between hormone networks and the brain. Patients with CAH, indeed, can be overexposed to corticotropin, 17-hydroxyprogesterone, and androgens and underexposed to cortisol and aldosterone, before and after birth. Our findings, obtained from patients with CAH, part of whom had a long-term follow-up, indicate that brain white matter is frequently, subclinically, and steadily affected.

White matter involvement might be due to the hormonal imbalance during brain maturation. Glucocorticoids inhibit the proliferation of oligodendrocyte precursors,<sup>6</sup> while hydrocortisone exerts a trophic effect on



**Figure 2.** Focal white matter abnormalities located mainly in the deep lobar white matter in an 18-year-old man affected by salt-wasting congenital adrenal hyperplasia (A) and in the splenium of the corpus callosum (arrow) in a 19-year-old man affected by simple virilizing congenital adrenal hyperplasia (B).

glial cells<sup>7</sup>; therefore, the imbalance of these hormonal factors during oligodendroglial differentiation might influence the myelination process.<sup>8</sup>

Corticosteroid treatments could also contribute to white matter abnormalities. Sometimes, patients with CAH require supraphysiological doses of glucocorticoid to adequately suppress adrenal androgen production.<sup>9</sup> Exogenous glucocorticoid replacement cannot precisely mimic the natural circadian variation of cortisol secretion<sup>10</sup>; under these conditions, high-dose glucocorticoid levels could interfere with normal myelination.<sup>11</sup>

Some of the white matter abnormalities could also be interpreted as microangiopathic damage. In this regard, aldosterone could have a relevant role, being one of the major stimulators of collagen synthesis and fibroblast proliferation via activation of local mineralocorticoid receptors. Aldosterone is synthesized *de novo* in the brain and could play a direct local regulatory function on the cerebral arterial structure.<sup>12</sup> Therefore, aldosterone deficiency in CAH could lead to subclinical cerebral ischemia.

Six patients with CAH had focal white matter abnormalities that were located in the periventricular region and in the corpus callosum. Similarly, some patients with CAH described by Nass et al<sup>2</sup> showed white matter lesions, with localizations that were typical of demyelinating diseases (located in the corpus callosum and cerebellum). In addition, we have described in 2004 a patient whose condition was diagnosed at birth as the salt-wasting subtype of CAH in whom relapsing-remitting multiple sclerosis developed.<sup>4</sup> The fact that a susceptibility locus for multiple sclerosis is in the HLA region that comprises the *CYP21* genes suggests a possible genetic link between multiple sclerosis and CAH. Anyway, our follow-up data indicate that white matter ab-

normalities, when present, never modified up to 10 years, and that no MRI abnormality appeared after a first normal examination. Thus, we could argue that white matter involvement is not an expression of an evolutionary pathology (as expected in multiple sclerosis), but could be a precocious and stable event, as further supported by normal MRIs in the 3 patients with the late-onset form.

To summarize, subclinical brain white matter involvement is frequent in CAH. It could be the consequence of a combination of multiple events due to hormonal imbalance and corticosteroid treatment. It is also presumable that these events occur early and affect the brain's physiological development. Finally, a possible link with demyelinating diseases must be considered.

More extensive studies are required to better define the relationships between brain involvement and different CAH phenotypes and treatment regimens. However, our findings could already improve clinical practice. It is quite common to meet young persons with brain MRI white matter abnormalities who do not have the corresponding neurological signs and symptoms. In these cases, MRI findings often remains inexplicable. Sometimes diagnoses of suspected demyelinating disease or of cerebral microangiopathy of unknown cause are made. Hence, neurological and instrumental assessment and follow-up are planned, without upgrading the diagnostic explanation. In these persons, a suggestion of CAH should be considered as well as the fact that carrier frequency of CAH in the general population has been estimated to be up to 9% in 2005.<sup>13</sup> Accordingly, appropriate information about linear growth, sexual development, and reproductive problems should be recorded and, if the diagnostic suggestion is clinically substantiated, hormonal tests should also be performed.

Accepted for Publication: October 16, 2005.

**Correspondence:** Roberto Bergamaschi, MD, Multiple Sclerosis Center, Neurological Institute "C. Mondino," Via Mondino 2, 27100 Pavia, Italy (roberto.bergamaschi@mondino.it).

**Author Contributions:** *Study concept and design:* Bergamaschi, Livieri, and Bastianello. *Acquisition of data:* Bergamaschi, Livieri, Uggetti, Candeloro, Egitto, and Pichiecchio. *Analysis and interpretation of data:* Bergamaschi, Candeloro, Livieri, and Uggetti. *Drafting of the manuscript:* Bergamaschi, Livieri, Uggetti, Candeloro, and Pichiecchio. *Critical revision of the manuscript for important intellectual content:* Pichiecchio, Cosi, and Bastianello. *Study supervision:* Cosi and Bastianello.

**Funding/Support:** This study was supported in part by grant Ricerca Corrente 2000 from the Italian Ministry of Health, Rome, Italy.

## REFERENCES

1. Sinforiani E, Livieri C, Mauri M, et al. Cognitive and neuroradiological findings in congenital adrenal hyperplasia. *Psychoneuroendocrinology*. 1994;19:55-64.
2. Nass R, Heir L, Moshang T, et al. Magnetic resonance imaging in the congenital adrenal hyperplasia population: increased frequency of white-matter abnormalities and temporal lobe atrophy. *J Child Neurol*. 1997;12:181-186.
3. Merke DP, Fields JD, Keil MF, Vaituzis AC, Chrousos GP, Giedd JN. Children with classic congenital adrenal hyperplasia have decreased amygdala volume: potential prenatal and postnatal hormonal effects. *J Clin Endocrinol Metab*. 2003;88:1760-1765.
4. Bergamaschi R, Livieri C, Candeloro E, Uggetti C, Franciotta D, Cosi V. Congenital adrenal hyperplasia and multiple sclerosis. Is there an increased risk of MS in individuals with congenital adrenal hyperplasia? *Arch Neurol*. 2004;61:1953-1955.
5. Wahlund LO, Barkhof F, Fazekas F, et al. A new rating scale for age-related white matter changes applicable to MRI and CT. *Stroke*. 2001;32:1318-1322.
6. Alonso G. Prolonged corticosterone treatment of adult rats inhibits the proliferation of oligodendrocyte progenitors present throughout white and gray matter regions of the brain. *Glia*. 2000;31:219-231.
7. Warringa RA, Hoeben RC, Koper JW, Sykes JE, van Golde LM, Lopes-Cardozo M. Hydrocortisone stimulates the development of oligodendrocytes in primary glial cultures and affects glucose metabolism and lipid synthesis in these cultures. *Brain Res*. 1987;431:79-86.
8. Gago N, Akwa Y, Sananes N, et al. Progesterone and the oligodendroglial lineage: stage-dependent biosynthesis and metabolism. *Glia*. 2001;36:295-308.
9. Merke DP, Bornstein SR, Avila NA, Chrousos GP. Future directions in the study and management of congenital adrenal hyperplasia due to 21-hydroxylase deficiency [NIH conference]. *Ann Intern Med*. 2002;136:320-334.
10. Dallman M. Corticosterone replacement in adrenalectomized rats: insights into the regulation of ACTH secretion. In: Rose F, ed. *The Control of the Hypothalamic Pituitary Adrenocortical Axis*. Madison, Conn: International Universities Press; 1990:399-426.
11. Huang WL, Harper CG, Evans SF, Newnham JP, Dunlop SA. Repeated prenatal corticosteroid administration delays myelination of the corpus callosum in fetal sheep. *Int J Dev Neurosci*. 2001;19:415-425.
12. Verpillat P, Alperovitch A, Cambien F, Besancon V, Desal H, Tzourio C. Aldosterone synthase (CYP11B2) gene polymorphism and cerebral white matter hyperintensities. *Neurology*. 2001;56:673-675.
13. Baumgartner-Parzer SM, Nowotny P, Heinze G, Waldhausl W, Vierhapper H. Carrier frequency of congenital adrenal hyperplasia (21-hydroxylase deficiency) in a middle European population. *J Clin Endocrinol Metab*. 2005;90:775-778.

## Announcement

Visit [www.archneurolog.com](http://www.archneurolog.com). As an individual subscriber, you may elect to be contacted when a specific article is cited. Receive an e-mail alert when the article you are viewing is cited by any of the journals hosted by HighWire. You will be asked to enter the volume, issue, and page number of the article you wish to track. Your e-mail address will be shared with other journals in this feature; other journals' privacy policies may differ from *JAMA & Archives Journals*. Sign up to receive an e-mail alert when articles on particular topics are published.